

## CASE REPORT

# Hemolytic Anemia Caused by Kinking of Dacron Grafts Implanted in Repair of after Aortic Dissection

Feridoun Sabzi, Fahimeh Ghasemi, Atefeh Asadmobini

### ABSTRACT

**BACKGROUND:** Hemolytic anemia caused by a kinked Dacron graft is a rare complication after repair of acute aortic dissection. We present a case of hemolytic anemia due to kinking of previously implanted Dacron graft for ascending aorta dissection treated by surgery and replaced with new Dacron.

**CASE DETAILS:** We report a case of postoperative hemolytic anemia with kinking of the graft at the outer graft layer and intra luminal bulging of the inner graft. Postoperative computed tomography showed Dacron graft kinking at the mid part of the graft. Transthoracic echocardiography (TTE) revealed good function of repair aortic valve. Upon the redo midsternotomy, we found moderate kinking of the graft at the outer graft layer and intra luminal bulging of the inner graft. We performed reconstruction of the aortic root with a new Dacron.

**CONCLUSION:** The careful literature review showed that there are some few cases of hemolytic anemia after dissection, but no cases in which hemolytic anemia occurred in a patient with kinked Dacron graft after surgery delete treated by replacement of kinked Dacron graft by new one.

**KEYWORDS:** Hemolytic anemia, Surgical repaired aortic dissection, Aortic graft kinking

DOI: <http://dx.doi.org/10.4314/ejhs.v26i5.13>

### INTRODUCTION

Acute ascending aortic dissection (AAD) as a fatal disease of the aorta without surgical intervention is associated with high morbidity and mortality (1). However, preoperative rupture of the aorta, hemodynamic instability, weak and fragile aortic wall make open intervention a difficult problem. Surgeon's attention to the reinforcement of proximal anastomosis, native aortic size mismatch with Dacron graf and fragility of aortic wall are key factors in probable intraoperative kinking of Dacron graft that may be a basis for hemolysis. We present a case of hemolytic anemia due to kinking of previously implanted Dacron graft for ascending aorta dissection treated by surgery and replaced with new Dacron.

### CASE REPORT

A 45 years old man had an urgent aortic root replacement due to impending rupture of ascending aorta in the Imam Ali Hospital of the Kermanshah University of Medical Science in

February 2015. The primary surgery was performed under moderate hypothermia cardiopulmonary bypass (right femoral artery cannulation, single right atrial cannulation).

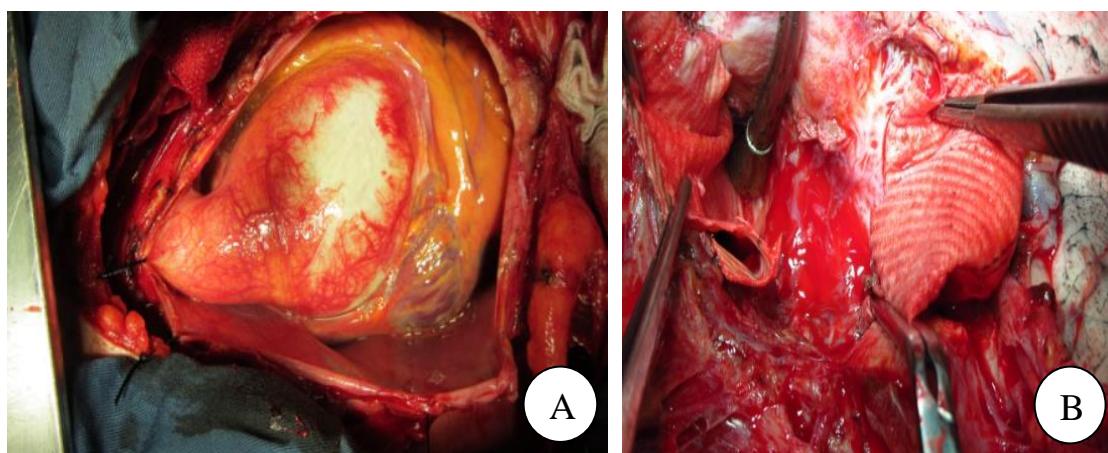
After aortic cross-clamping, the ascending aorta was opened transversely and the myocardium was arrested with a cold cardioplegia (1200 ml) infused into the coronary ostia. Topical cooling with cold water and ice slash was performed during the procedure. The aortic tear that involved 70% of the aortic circumference was detected on the left posterior surface of the ascending aorta (4 cm above the aortic annulus) (Figure 1A, B). The false lumen ended blindly 3 cm below the innominate artery and below the aortic cross-clamp site. The ascending aorta was completely transected above the right and the left coronary ostium level and prepared for distal anastomosis and coronary ostium implanting on the Dacron graft (Figure 1C). The aortic valve that was not suitable for repair was excised and the annulus size was measured. The good tissue

<sup>1</sup>Cardiovascular Research Center, Kermanshah University of Medical Sciences, Kermanshah, Iran

**Corresponding Author:** Atefeh Asadmobini, Email: a.asadmobini@gmail.com

quality of the ascending aorta wall in ostium area gave an opportunity for the creation of the 'buttons' technique to incorporate coronary Ostia in the Dacron graft (Figure 1D). The sewing ring of the composite valve graft was implanted to the aortic annulus. The full thickness of the aortic wall tissue around the left coronary ostium was sutured with 6-0 prolene suture to the opening in the Dacron conduit. Then, the right ventricle was pressurized with short clamping of the venous line to determine the proper site of the right coronary ostium to the graft. At that time, no major leaking at the level of the left or right coronary ostium anastomosis was detected. The right coronary ostium anastomosis to the graft was performed in the same method with prolene 6-0. Then, after the

graft length was appropriate, the distal anastomosis of the conduit to distal aorta was performed with a continuous 4-0 polypropylene suture (Figure 1E). Although venous bleeding from the tissue surrounding the coronary buttons was severe and persistent after routine rewarming period, we decided to control the bleeding from the dissected tissue around the right coronary ostium with pledget 4-0 prolene by attachment of the remnant of proximal ascending aorta wall for the conduit. Partial hemostasis was found with some leaking from the venous blood from the tissue around the right ostium, and the patient was weaned from cardiopulmonary bypass without difficulty.



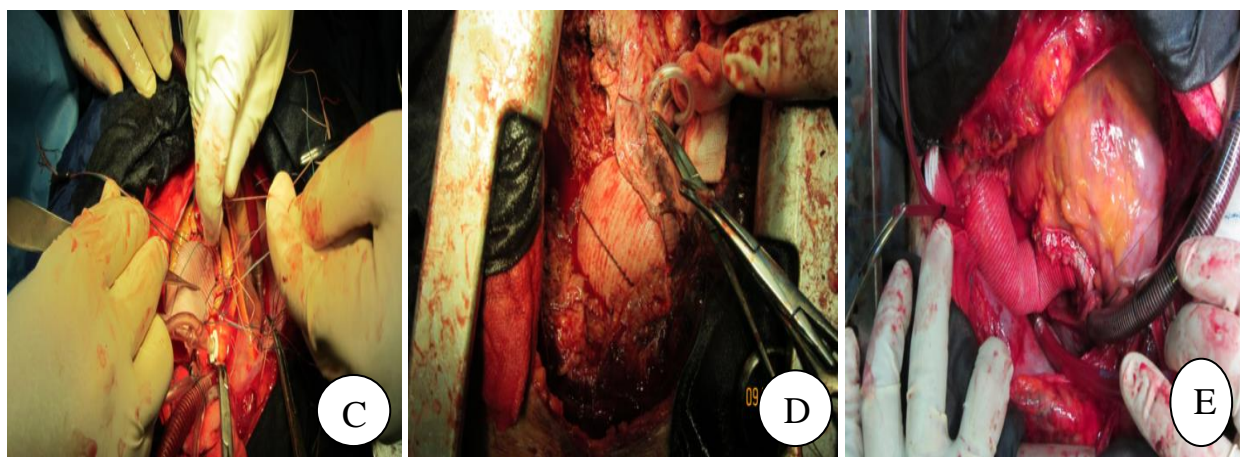
**Figure 1:** (A) Shows dissected aneurysm of the ascending aorta. (B) Shows resection of mid portion of Dacron graft.

This case had a history of postoperative bleeding that was controlled by mediastinal packing during the primary operation. The postoperative course was complicated by dropping the serum hemoglobin level, and the patient was admitted for a multiple episodes at follow-up visit in clinic. At last admission (two months later), he was complaining of dyspnea, lower extremity edema, pale skin and yellow urine. He was also complaining of chest pain, poor general condition and fatigue with gross change of urine color to hematuria for three days. The serum Hb level was 8 (mg/dl), lactate dehydrogenase (LDH) enzyme 2500 (IU/L), free Hb 60 (mg/dl), hematocrit 30%, relative reticulocyte count 9%, haptoglobin 7 (mg/dl), total bilirubin 8 (mg/dl). Three respective blood cultures showed negative results. Peripheral blood smear showed many schistocytes, however,

the Coombs' test was negative. Bone marrow aspiration was performed to rule out the possibility of an underlying hematologic dyscrasia, and it showed marked increased bone marrow erythropoiesis but no cells representative of a malignancy were diagnosed. Mycoplasma pneumonia IgM antibody was negative and Urinalysis was strongly positive for both hemoglobin but not RBCs. Immunological and infectious causes of RBC destruction and cold agglutinin were negative. Multiple Thrombophilia tests such as protein S-C deficiency and G6PD was normal. In the primary operation, the patient did not received hepatotoxic drugs or hemolytic drugs. Physical examination showed blood pressure of 80/30 mmHg, pulse of 114 bpm, body temperature of 36.5°C, yellow skin color appearance and red-yellow urine color while eye

exam showed jaundice. In the physical examination, the cardiac examination was evidence of prominent grade 2/6 systolic murmurs that was best heard at the mid sternal part with radiation into the anterior left chest. Transoesophageal echocardiography (TTE) revealed presence of normal function of prosthetic composite graft and valve. There is no evidence of vegetation in Dacron or valve in the setting of normal left ventricular function and no gradient across the Dacron tube. These data suggested a mechanical destruction of red blood cells. Without para valvar leak, our attention was directed to the geometrical property of tube Dacron. Computed tomography showed some kinking of the mid portion of Dacron tube. With normal coronary arteries in previous angiography, ST-segment changes on electrocardiogram and typical chest

pain was indicative of severe dropping of the serum Hb and ischemic anemia. Finally, we supposed a hemolytic mechanism by fragmentation of red blood cells across of tube graft by a systolic turbulent flow. However, we could not detect this accelerated flow change by TTE or by transesophageal echocardiography. Clinical signs, symptoms and electrocardiogram ischemic changes were resolved by blood cell transfusion. However, blood urea nitrogen (BUN) and creatinine were not recovered, and the patient's heart failure was gradually exacerbated in the next two weeks when his serum Hb dropped again and weakness and fatigue resumed. Thus, we scheduled to do a redo-operation to reconstruct the kinked Dacron tube and to explore the kinked lesion causing hemolysis.

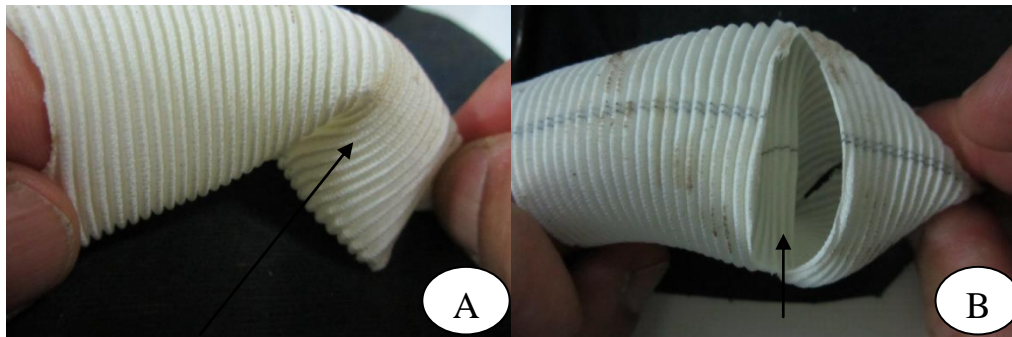


**Figure 1:** (C) Shows primary step in reconstruction of aortic root by composite graft. (D) Shows reconstructed of kinked Dacron tube that was wrapped by surrounding tissue for controlling of bleeding from dissected pulmonary artery and previous fibrotic tissue around the old Dacron tube. (E) Shows final reconstruction of aneurysm by Bentall operation. Bleeding from surrounding tissue of right coronary artery stump was controlled by 5/0 pledgeted sutures that showed by transverse arrow.



During the operation, we observed that there was an inner bulging of Dacron graft as a crescent ridge in the internal wall of the graft that was covered by endothelium (Figure 2A, B). This old graft was resected in mid portion and replaced by new segment of graft. We had not found any paravalvular leak around the aortic prosthetic

valve and did not need an additional repair. Postoperatively, gross hematuria and hemolytic anemia recovered completely as the LDH level and bilirubin serum level. In 6 months' follow-up visit, he was in clinical good condition with resolving congestive heart failure (CHF), and renal failure as his laboratory abnormality returned to normal level.



**Figure 2:** (A) Shows preoperative schematic image of twisted Dacron tube (black arrow). (B) Shows internal bulging of Dacron graft as result of torsion (black arrow).

## DISCUSSION

Hemolytic anemia (HA) as a very rare event could be suspected in any open surgical intervention around the aortic root, ascending arch and descending aorta or patent ductus arteriosus (PDA) (2-3). Other anatomical abnormalities that may be leading to hemolysis in non-operated patient include: subprosthetic valve caused by pannus formation, native or prosthetic valve stenosis, aortic valve calcification, PDA occlusion by interventional method, aortic regurgitation (AR), and regurgitated blood across the aortic valve to mitral prosthetic ring. In our case, an important factor, HA, led us to schedule a reoperation for the patient. In the concept of hemolytic anemia following an operation for aortic root, perivalvular leakage through the valve ring or through the perivalvular fistula to any cardiac chambers is the most common cause. Graft distortion due to the mismatch diameter size of the native and dissected aorta proximal to the Dacron graft or long size of Dacron was noted as a cause of hemolytic anemia in our patient. One study

reported a subject with an aortic root operation that proximal pseudo aneurysmal formation following dehiscence of the suture line compressed the external graft and by making a supravalvular aortic stenosis led to turbulent blood flow and HA(4). Matsuura K et al reported hemolytic anemia developed by stenosis of the proximal part of aorto-graft anastomosis for felt strip, which was implanted inversely to reinforce the proximal suture line (3). In a study by Shingu, teflon felt strips were implanted to sutures to reinforce the proximal anastomosis on the fragile, dissected aortic wall to Dacron tube to prevent future residual dissection and postoperative serious bleeding, but the postoperative course was complicated by proximal aortic stenosis and HA(5). Therefore, multiple surgical trick was recommended for reinforcement of the proximal anastomosis by prosthetic strip or pledged; each one may caused HA in some patients. In the present report, the inner graft wall was bulging as a ridge in the direction of blood flow in the mid posterior segment of graft. In a previous operation, the graft was trimmed proximally longer and more

obliquely in the proximal end; these two factors led to kinking and distortion of graft. However, the suture line of the proximal anastomosis had no evidence of infection or pseudo aneurysms that may be considered as a probable cause of HA. In some cases, abnormal direction of blood flow into the dissected false lumen lead to dilatation of false lumen and compression of true lumen. This abnormality led to increase collision of red cell against constricted true lumen and with the increasing shear stress on blood cells. However, we could not found turbulent flow induced by Dacron distortion by TTE. We speculated that the kinked inner wall Dacron graft was the cause of graft aortic stenosis and hemolytic anemia. In our case, HA, CHF and poor general condition caused by Dacron graft distortion urged us to perform a redo- operation. Although Dacron graft kinking is a rare but tremendously serious complication, because it often requires reoperation on the Dacron tube. Kinking of Dacron graft may be attached to the internal table of sternum and predisposed to catastrophic bleeding during reinterring to the mediastinum. The aortic valve was replaced with a prosthetic valve during the previous operation for aortic root. However, no paravalvular leak or dissection was found, which is not considered as a cause of HA in this phase. In our patient, we supposed that the cause of HA was not other anatomic distortion such as redissection, supra- valvular aortic stenosis or strip felt of pledges sutures. No evidence of paravalvular leak, fistula or sub aortic leaflet pannus in the aortic root or Dacron graft. Also, no evidence of the dissection flap in the native aorta or an inverted strip was observed in the operation field. The mechanism responsible for the occurrence of HA in this case appeared to be kinked Dacron graft.

We believe that kinking of the aortic vascular graft may be one of the complications seen in this kind of operation, causes severe intravascular hemolysis and necessitates a second intervention. We suggest that the kinking of the aortic Dacron graft may be related to an inappropriate Dacron graft length. We also think that careful measuring of Dacron graft in intraoperative period is important. The important method for preventing Dacron graft torsion is pressurizing the right ventricle by temporary clamping of venous return. Then, the right and the left ventricles were pressurized to determine the proper site of the

right coronary ostium to the graft. At that time, if major kinking of Dacron graft in proximal or mid or distal part of Dacron at the level of the left or right coronary ostium anastomosis had been detected, it would have been corrected. The right coronary ostium anastomosis to the graft was performed in the same method with Prolene 6-0. Severe hemolysis was attributable to the impairment of blood flow by outburst of blood at the location of the kinking aortic vascular graft. A second operation was performed because the renal function of the patient decreased progressively while hemolysis symptoms increased. After the second operation, hemolysis on peripheral blood smears disappeared and renal function showed progressive improvements.

As our case report suggested, hemolytic anemia in the chronic phase of a surgically repaired ascending aortic dissection is a rare but lethal complication requiring a reoperation with a various mechanisms. It is combined with not only supra- valvular aortic stenosis, but also AR. Thus, a simple and accurate method to reinforce the dissected wall is necessary despite its fragility.

**REFERENCES**

1. Bhamidipati C, Ailawadi G. Acute complicated and uncomplicated Type III Aortic Dissection: An endovascular perspective. *Semin Thorac Cardiovasc Surg* 2009; 21:373-86.
2. Nakamura Y, Ogino H, Matsuda H, Minatoya K, Sasaki H, Kitamura S. Hemolytic anemia after operation for aortic dissection using Teflon felt strips. *Ann Thorac Surg* 2008; 85:1784-87.
3. Matsuura K, Ogino H, Minatoya K, Sasaki H. Aortic stenosis caused by the felt strip used in repair for acute aortic dissection. *Interact CardioVasc Thorac Surg* 2004; 3:41-3.
4. Vilacosta I, Camino A, San Roman JA, et al. Supravalvular aortic stenosis after replacement of the ascending aorta. *Am J Cardiol* 1992; 70:1505-07.
5. Shingu Y, Aoki H, Ebuoka N, et al. A surgical case for hemolytic anemia after ascending and total arch replacement. *Ann Thorac Cardiovasc Surg* 2005; 11:416-18.